


PATIENT

Lego MacAloney

SPECIES

Canine

BREED

Yorkie Mix

SEX

Male Neutered

AGE

4 years

WEIGHT

7.9kgs

PRESENTING CLINICAL SIGNS

History: Presents today with a 3 month hx of panting and difficulty breathing. Was a progressive change - originally it was intermittent but now its all the time. Has decreased appetite and chokes when trying to drink. Has zero energy. If he gets worked up he will actually vomit. T41C, very worked up requiring sedation (with butorphanol) on admission. Loud crackles in all lung fields, distended abdomen, unable to auscultate heart over breathing. meds; Furosemide 20mg BID-improved significantly on meds

Abnormal PE/Chem/CBC/UA Results: HR ~ 180/RR Panting hard Radiographs reveal a very globoid heart in all 3 views. On both lateral views there is a loss of the cardiac waist with mild distension of the cardiac vessels. There is a mild interstitial lung pattern in all lung fields. The liver appears moderately enlarged in the R lateral. There is moderate gas in the stomach, with a normal gastric axis. No obvious tracheal narrowing or deviation.

ECHOCARDIOGRAM FINDINGS

2D, m-mode, color flow and doppler imaging is available. Normal mitral valve leaflets with no prolapse into the left atrial lumen. No mitral regurgitation with no left atrial dilation. Normal LV diameter with adequate myocardial function. The tricuspid valve appears normal with trivial regurgitation. Normal right atrial and ventricular diameter and morphology indicating no overt evidence of pulmonary arterial hypertension. The pulmonic and aortic valves are normal in morphology and mobility. Normal pulmonic and aortic outflow velocities with laminar flow. No obvious aortic or pulmonic insufficiency. No pericardial or pleural effusion noted. No obvious cardiac masses.

CARDIAC CHART
INTERPRETED BY

 Maggie Machen Lamy,
 DVM DACVIM
 (Cardiology)

IMAGING
PERFORMED BY

Kelly Reschny, CVT

HOSPITAL NAME

 Yates Veterinary
 Hospital

REFERRING VET

Dr. Merkel

INVOICE

24154

DATE

5/11/22

CANINE CARDIAC PARAMETERS	MR VMAX (m/s)	TR VMAX (m/s)	LA/AO (Boon method)	LA/AO (Heart Base; Swe)	FS (%)	EF (%)	EPSS (cm)
NORMAL PARAMETER	4.5-5.5	<2.7	1.3	<1.6	28-40	40-100	<0.6
PATIENT	NA	NA	1.26	1.3	50	84	1.2
CANINE CARDIAC PARAMETERS	HR (BPM)	AV VMAX (m/s)	PV MAX (m/s)	BODY WEIGHT (kg)	LA 2D short axis Base view (cm)	LVIDd Avg; 2D and m-mode short axis (cm)	LVIDs Avg; 2D and m-mode short axis (cm)
NORMAL PARAMETER	50-100	0.7-1.7	0.7-1.6	BELOW	BELOW	BELOW	BELOW
PATIENT	147	1.9	1.7	8	1.3	2.1	1.0
*Normal chamber parameters expressed as a mean value (SD)				3	1.27 (5.3)	2.46 (2.46)	1.36 (5.5)
BODY WEIGHT DEPENDENT PARAMETERS				5	1.40 (4.5)	2.74 (5.2)	1.60 (4.7)
<i>*Note: All measurements based upon multi-modal images and methods. An average value is reported.</i>				10	1.50 (3.8)	3.27 (3.5)	2.06 (3.1)
				15	1.83 (2.0)	3.71 (2.4)	2.43 (2.1)
				20	2.02 (1.9)	4.14 (2.2)	2.80 (2.0)
				25	2.18 (2.4)	4.48 (2.9)	3.10 (2.5)
				30	2.33 (3.3)	4.83 (3.9)	3.39 (3.4)
				35	2.48 (4.3)	5.17 (5.0)	3.69 (4.5)
				40	2.62 (5.2)	5.48 (6.1)	3.96 (5.4)
				50	2.88 (7.1)	6.07 (8.3)	4.46 (7.4)

Adapted from June Boon, Veterinary Echocardiography, 1998
 Rishniw M and Hollis NE, J Vet Intern Med 2000; 14:429-435
 Hansson et al, Vet Rad and Ultrasound 2002
 Bonagura et al. Echocardiography: principles of interpretation, Vet Clin North Am 15:1177, 1995



PATIENT

Lego MacAloney

SPECIES

Canine

BREED

Yorkie Mix

SEX

Male Neutered

AGE

4 years

WEIGHT

7.9kgs

INTERPRETED BY

Maggie Machen Lamy,
DVM DACVIM
(Cardiology)

IMAGING PERFORMED BY

Kelly Reschny, CVT

HOSPITAL NAME

Yates Veterinary
Hospital

REFERRING VET

Dr. Merkel

INVOICE

24154

DATE

5/11/22

INTERPRETATION OF THE FINDINGS & FURTHER RECOMMENDATIONS

Overtly normal cardiac dimensions and function, with no obvious dysfunction or dilation of the left heart. No significant valvular leaks are visualized, and no evidence of pulmonary hypertension.

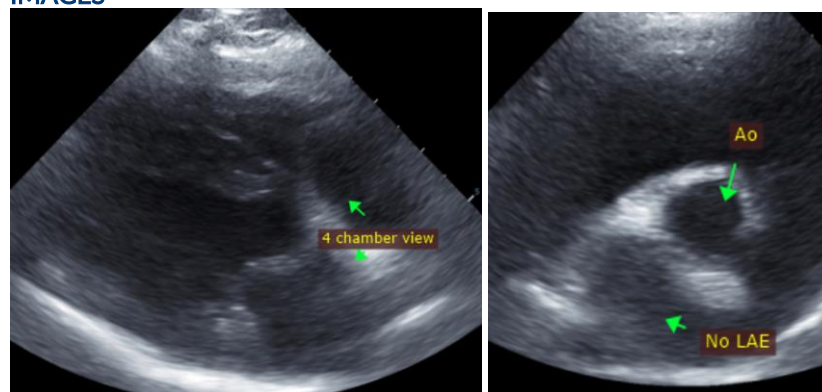
These findings would suggest cardiomegaly is a normal variant, which is common in this breed.

No cardiac medications are indicated at this time as the cough appears non-cardiac in origin. **Lasix should be safely discontinued.** Continued work up for infectious/inflammatory respiratory causes is recommended. Options include Baytril or similar antibiotic, anti-inflammatory prednisone, aggressive hydrocodone, etc. If refractory, may consider TTW/BAL for further information.

Monitor for development of a heart murmur, cough, labored breathing, exercise intolerance or collapse episodes.

Chronic respiratory issues can lead to pulmonary hypertension if poorly controlled and a recheck echocardiogram is recommended should any exertional syncope/dyspnea occur, or a murmur be noted in the future.

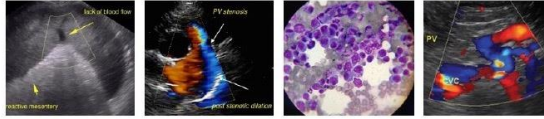
IMAGES



The information and recommendations provided are based on the images presented by the referring veterinarian. No evaluation can be communicated regarding pathology that was not visible in the image/video clips provided.

Thank you for this referral. If the clinical or image interpretation does not parallel your findings or if I can be of any further assistance, please contact me.

Maggie Machen Lamy, DVM
Diplomate of the American College of Veterinary Internal Medicine (Cardiology)
info@sonopath.com



PATIENT

Lego MacAloney

SPECIES

Canine

BREED

Yorkie Mix

SEX

Male Neutered

AGE

4 years

WEIGHT

7.9kgs

INTERPRETED BY

Maggie Machen Lamy,
DVM DACVIM
(Cardiology)

**IMAGING
PERFORMED BY**

Kelly Reschny, CVT

HOSPITAL NAME

Yates Veterinary
Hospital

REFERRING VET

Dr. Merkel

INVOICE

24154

DATE

5/11/22